

## HISTORY OF ONCOLOGY

---

# Charles-Emile Troisier (1844-1919) and the clinical description of signal node

Marianna Karamanou<sup>1</sup>, Konstantinos Laios<sup>1</sup>, Gregory Tsoucalas<sup>1</sup>, Nikolaos Machairas<sup>2</sup>, George Androutsos<sup>1</sup>

<sup>1</sup>Department of History of Medicine, Medical School, University of Athens, Athens; <sup>2</sup>Second Department of Surgery, Laiko University Hospital, Athens, Greece

### Summary

Charles-Emile Troisier's research concerning the enlarged left supraclavicular lymph node and its connection not only with gastric carcinoma but also with several other abdominal malignancies contributed to the diagnosis of cancer during the last part of the 19<sup>th</sup> century. Troisier's

name is connected along with that of his German colleague Rudolf Virchow (1821-1902) concerning the development of modern pathology.

**Key words:** abdominal neoplasia, history of oncology, left supraclavicular lymph node enlargement, Troisier's sign, Virchow's node

### Introduction

During the 19<sup>th</sup> century an amazing progress in pathology occurred, paving the way for the introduction of cellular pathology which was linked with the technological progress in industry, the improvement in microscopy lenses, the development of dyes for staining and the ability for cutting thin sections of tissues. In Germany, Rudolf Virchow (1821-1902) inaugurated histopathology as a method of investigation by examination of diseased tissues at cellular level. In addition to his leading work Virchow discovered that an enlarged left supraclavicular lymph node is one of the earliest signs of gastrointestinal malignancy, affecting mainly the stomach and less commonly the lung. This observation was made approximately simultaneously by his French colleague Charles-Emile Troisier (1844-1912). The eponyms of *Virchow's node* or *Troisier's sign* have been popularly used to this day [1].

In our article, we will highlight the life and contribution in oncology of Charles-Emile Troisier, a distinguished pathologist which his medical work is less known in the general medical community.

### Charles-Emile Troisier's life and work

Charles-Emile Troisier (photo) was born on April 16, 1844 in the commune of Savigny, department of Ardennes, France. He accomplished his primary studies in Reims and he also attended Reims School of Medicine [2].

In 1869, he was admitted in Paris Medical School as intern and in 1874 he presented his doctoral thesis entitled *Recherches sur les lymphangites pulmonaires* (Research on pulmonary lymphangitis), currently known under the term *pulmonary lymphangitic carcinomatosis*. In his thesis, Troisier explained the ability of tumors to spread through the lymphatics of the lung and he received, for his remarkable description, the Silver Medal from Paris Medical School [3].

At his 36 years, he was appointed Associate Professor in the chair of Pathology and Therapeutics and in 1901 he was elected Member of the National Academy of Medicine. Moreover, Troisier was member of the Anatomical Society and Vice-President of Biology Society [3].

Being an excellent pathologist and clinician,



**Photo.** The French Pathologist Charles-Emile Troisier (1844-1919).

Troisier's lectures were attended by numerous students who appreciated his medical accuracy, the novelty of his ideas and his medical experience.

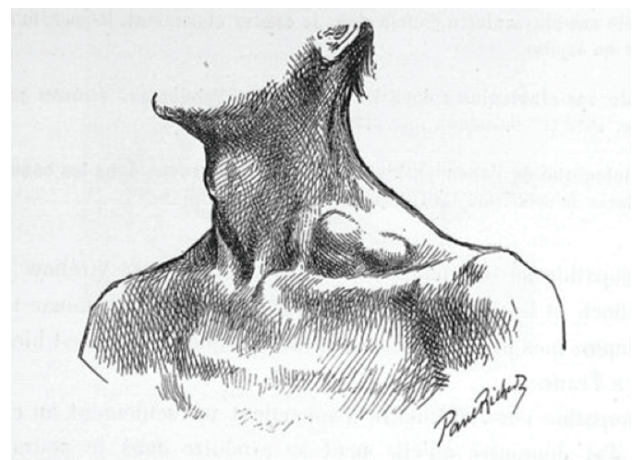
Apart from the description of the enlarged left supraclavicular lymph node and its connection with cancer, Troisier published several works on meningitis, pleurisy, hereditary syphilis and rachitis (in collaboration with his colleague Joseph Marie Jules Parrot), rheumatismal nodosities, phlegmasia alba dolens, and he also first described bronzed diabetes (or hemochromatosis) which is still referred to as *Troisier-Hanot-Chauffard* syndrome, including hepatomegaly and diabetes mellitus [2,3].

Charles Emile Troisier died in Paris on December 15, 1919. Among his descendants it's worth mentioning Professor Jean Troisier (1881-1945), a distinguished bacteriologist in Institute Pasteur who was leading the experimental department of non human primates financed by his friend the Greek princess and Freud's pupil Marie Bonaparte [4]; Solange Troisier (1919-2008) a gynecologist who participated actively in French resistance during WWII and was also known for her work in prisons; and the distinguished orthopedician Olivier Troisier (1921-2008) [5].

## Troisier's node

Known from Virchow's work and after on by the work of Eduard Heinrich Henoch (1820–1910) and Wilhelm Olivier Leube (1842–1922) as a sign of gastric cancer, the enlarged supraclavicular lymph node (Figure 1) received also the attention of Troisier who connected it, in his turn, with several types of malignancies. As he mentioned: "The supraclavicular adenopathy is not a sign only of gastric cancer. I demonstrated that it could occur during any kind of abdominal malignancy affecting also pancreas, liver, kidneys, ovaries, and testes. It does not indicate the exact location of malignancy but it reveals the cancerous nature of the affection which could be at that stage, generalized and inoperable. The enlarged supraclavicular lymph node can be associated with other adenopathies in the body but usually it is a sole sign, appearing several months before death and preceding cancer cachexia" [2].

Describing the location of lymph nodes, Troisier stated: "One or several ganglions are present over the middle third of the clavicle in the supraclavicular triangle or behind the clavicular fascicle of the sternocleidomastoid muscle. The adenopathy could be located in both supraclavicular sides but it has a predominance for the left supraclavicular fossa. These ganglions are isolated or could be fused. At the beginning they could be felt only by careful palpation but at an advanced stage they could form a projection deforming the supraclavicular fossa. The lymph nodes are mobile, enlarged, hard without adherence in the skin and painless. Rarely, phenomena of compression could appear" [2].



**Figure 1.** Enlarged left supraclavicular lymph node. Source Troisier EC. Titres et travaux scientifiques. Paris, Masson et Cie, 1901, p 18.

Trying to explain the proliferation of a neoplasm in the supraclavicular lymph nodes Troisier believes that it occurs by the infiltration of tumors in the prevertebral ganglions [2].

Moreover, he points out that physicians should always palpate the supraclavicular region in patients with symptoms of abdominal diseases. However, he states that enlarged lymph nodes in that area could be seen also in several other diseases such as tuberculosis and syphilis and physicians should make a differential diagnosis based on patient's medical history, detailed clinical examination and clinical evolution of the disease. In cases of diagnostic uncertainty, he suggests the surgical removal of the node and its microscopic examina-

tion for accurate diagnosis [2].

## Conclusion

The detailed description of the enlarged supraclavicular lymph node and its clinical interpretation is well presented in the Troisier's work. Its connection not only with gastric carcinoma but also with several other carcinomatous and pathological entities and the importance of pathological examination is also pointed out in his work. In a period where tumor markers and imaging tests for the detection of cancer did not exist, Troisier's contribution in cancer diagnosis remains of considerable value.

## References

1. Morgenstern L. The Virchow-Troisier node: A historical note *Am J Surg* 1979;138:703.
2. Troisier EC. Titres et travaux scientifiques. Paris, Masson et Cie, 1901, pp 1-63.
3. Laverran A. Décès de M. le Dr. of Troisier. Académie Nationale de Médecine, 1919.
4. Huguet F. Jean Troisier. In : Les professeurs de la faculté de médecine de Paris, dictionnaire biographique 1794-1939. Paris, CNRS édition, 1991, pp 480-481.
5. Troisier S. Une sacrée bonne femme. Paris, La Palatine, 2003.

## Erratum

*In Volume 19, no.3, 2014 issue, in the article appearing on pages 698-704, the abbreviated first author's name appears as Wang Y. The correct name's abbreviation is Wang YC.*